

## THE EFFECT OF AN INTENSIVE PHYSIOTHERAPY PROGRAM FOLLOWING BOTULINUM TOXIN INJECTION IN THE TREATMENT OF CHILDREN WITH IDIOPATHIC CLUB FOOT

Abdulrahman M Ali<sup>1</sup>, Mohamed B. Ibrahim<sup>1</sup>, Mohamed I. Elsofy<sup>2</sup>, Sara Y. Elsebahy\*<sup>1</sup>

<sup>1</sup>Department of Physical Therapy for Pediatrics, Faculty of Physical Therapy, Kafr El-Sheikh University, Egypt; <sup>2</sup>Department of Orthopedic Surgery, Faculty of Medicine, Zagazig University, Egypt.

### Abstract

**Background:** Although relapse and residual equinus are still problems, idiopathic clubfoot, a common congenital abnormality, usually responds well to the Ponster technique. This study examines whether administering injections of botulinum toxin type A (BTX-A) in conjunction with a rigorous physiotherapy regimen enhances treatment outcomes for young children.

**Methods:** BTX-A was injected into the gastrocnemius-soleus complex at the hind foot stall in a randomized of 46 babies with idiopathic clubfoot. divided into two groups. After one week, participants began a systematic eight-week intensive physiotherapy program IPT, and group 2 received a traditional physical therapy TPT programme that included. Passive stretching, manual mobilization, strengthening exercises, weight-bearing activities, and task-specific training. While TPT includes regular stretching exercises and orthotic bracing. At baseline, eight weeks, changes in ankle dorsiflexion, Pirani scores were used to evaluate the results.

**Results:** Both groups demonstrated statistically significant improvements in all measured variables after the intervention. However, the study group who took part in the rigorous physiotherapy program after receiving a BoNT-A injection showed significantly greater improvements in foot posture and lowered Pirani scores, ankle dorsiflexion range of motion.

**Conclusion:** Children with idiopathic clubfoot seem to respond better to treatment when an intense physiotherapy program is added after receiving BoNT-A injections. This improves foot alignment and functional outcomes. The use of a multimodal therapy approach in the management of this illness is supported by these findings.

**Keywords:** Intensive physiotherapy program, botulinum toxin injection, idiopathic club foot.

### Introduction

A common congenital condition, idiopathic clubfoot affects one out of every 1,000 babies. The etiopathogenesis has been connected to several genetic and environmental variables, including maternal age, alcohol use, oligohydramnios, smoking during pregnancy, and parental consanguinity. Distal arthrogryposis, myelomeningocele, amniotic bands, and other hereditary abnormalities are linked to about 20% of clubfeet,

Manuscrito recibido: 12/06/2025

Manuscrito aceptado: 17/06/2025

\*Corresponding Author: Sara Y. Elsebahy, Department of Physical Therapy for Pediatrics, Faculty of Physical Therapy, Kafr El-Sheikh University, Egypt

Correo-e: sarah\_elsehy2014@pt.kfs.edu.eg

and talar vertical is occasionally seen as well. Idiopathic clubfoot is the term for 80% of instances where the cause is unclear, with nearly 25% having a familial history (1). Numerous theories have been presented to describe the cause of Clubfoot, encompassing A cultivate mental arrest of the neuromuscular unit while birth within the womb, A compression impact within the uterine cavity because of insufficient space for the fetus, or genetic changes, even though none have been verified (2).

This deformity is known as "clubfoot" because of the way the foot resembles a golf club (3). The alterations associated with clubfoot are summed up by the acronym "CAVE": The letters C, A, V, and E stand for Cavus, Adduction, Varus, and Equinus, respectively (4). Congenital and acquired are the two primary categories into which clubfoot etiologist are usually divided. Clubfoot that is acquired typically develops after birth and can be further classified into neurogenic and vascular causes.

Neurogenic reasons include illnesses like poliomyelitis, meningitis, or damage to the sciatic nerve, whereas vascular causes include ailments like Volkmann ischemic paralysis (5). There are three categories of congenital clubfoot: idiopathic, neurogenic (like spina bifida and myelomeningocele), and syndromic (like arthrogryposis) (6). Clubfoot, which is idiopathic clubfoot, is the most prevalent kind. Conservative treatments usually work better for this isolated congenital anomaly, which is frequently bilateral (5). The most prevalent severe musculoskeletal birth abnormality in the US and the rest of the globe is idiopathic congenital clubfoot. The malformation will typically continue into adulthood with a marked decline in function and quality of life. The most popular and successful therapy for clubfoot in new-borns worldwide is the Ponseti procedure, which involves bracing the foot, Achilles tenotomy, and serial casting. When the Ponseti-trained professional (often a pediatric Orthopedic surgeon) administers the treatment, it is especially effective (7).

Numerous studies have examined the effects of botulinum toxin on local neuromuscular blocking, which has special benefits, particularly in lowering muscle stiffness and fostering functional recovery (8).

When combined with other rehabilitation techniques, BTX-A offers special benefits and characteristics for the management of post-stroke spasticity (9). Notable effectiveness:

Muscle stiffness and tension were considerably alleviated by BTX-A injection (10). The secondary outcome of thorough rehabilitation therapy: To enhance the therapeutic effect, BTX-A injection is typically used in conjunction with

other rehabilitation therapies such as physical therapy and exercise therapy. When paired with rehabilitation exercises like stretching and functional exercise training, BTX-A injections can help stroke patients' motor function and ease tense muscles (11).

The treatment of idiopathic clubfoot may benefit from the use of botulinum toxin A (BTX-A). By temporarily relaxing muscles, BTX-A may help people place their feet better and lessen the need for surgeries like Achilles tenotomise. Research has shown that the combination of BTX-A injections and casting can improve ankle dorsiflexion and overall foot alignment (12).

Physiotherapy is essential to the overall treatment of clubfoot. Ankle range of motion, functional mobility, and patient satisfaction have all been shown to improve with intensive physical therapy regimens, especially those that are phased in. By strengthening muscles and encouraging good foot mechanics, physiotherapy may improve results even more when combined with BTX-A treatment (13).

This study intends to assess the efficacy of a rigorous physiotherapy regimen in children with idiopathic clubfoot after receiving a BTX-A injection. By looking into how these therapies work together, we hope to ascertain whether they can enhance functional results and lessen the need for surgery in this patient group.

### Materials and Methods

#### Study Design and Participants

This study employed a prospective randomized controlled trial (RCT) design. Both males and females diagnosed with idiopathic club foot, new-born from birth to four months, were recruited from the King Abdulaziz Specialist Hospital, The Kingdom of Saudi Arabia. The participants were randomly assigned to two equal groups (n = 23 per group).

We enrolled children with idiopathic clubfoot who had achieved hind foot stall (persistent equinus despite forefoot rectification) and had finished initial serial casting according to the Ponseti procedure. Previous foot surgery and syndromic, neurogenic, or recurrent clubfoot were excluded. Informed consent was obtained from parents of eligible children who were invited to take part. The sample size was calculated using Cochran's formula with a confidence level of 95% (Z = 1.96), estimated proportion (p = 0.35), and margin of error (e = 0.148). The minimum sample size required was determined to be 46 participants, with 23 children allocated to each group.

### Study Design and Randomization

This research was carried out as an RCT. Microsoft Excel was used to perform the randomization. The RAND function is used to create random numbers in the second column, while patient names are listed in the first column. The research and control groups were randomly assigned to the participants based on the ascending order of these random numbers.

### Outcome Measures

#### Pirania score

The Pirani Score is a straightforward and trustworthy method for assessing clubfoot severity and tracking advancement (14). In order to assist in visualizing the problems in the underlying soft tissue and bony structure, this scoring system makes use of various foot images. Without the need for specialist equipment, a foot can be evaluated in less than a minute (15). The scale evaluates six clinical symptoms of deformity, which are separated into three components for the hind foot (stiff equinus, empty heel, and posterior crease) and three components for the midfoot (prominence of the lateral head of the talus, medial crease, and curved lateral border). The most severe deformity is indicated by a maximum score of 6, which is assigned to each symptom on a 3-point ordinal scale: 0 for normal, 0.5 for moderately abnormal, or 1 for severely abnormal. Piarani et al. (16) evaluated this clinical scoring system by comparing MRI and clinical scores, demonstrating the validity of the Piarni Score with strong inter-observer reliability. Jillian et al. found the Pirani Score to be a reliable measurement tool by plaster technicians for independent assessment of clubfoot. However, they highlight that prior training and supervision in the early phase are necessary. It is appropriate for use in both clinical and research contexts due to its exceptional interobserver and interrater reliability (17).

#### Passive ROM using electronic goniometer

When assessing joint mobility and treatment outcomes in children with idiopathic clubfoot, the measurement of passive range of motion (PROM) is an essential step. Compared to manual goniometry, electronic goniometers provide a more accurate, dependable, and objective approach. These tools offer digital angle measurements with low interobserver variability, which is especially useful for pediatric populations where accurate quantification is crucial (18). PROM is usually measured at the ankle joint (dorsiflexion with knee flexion and extension) in cases of idiopathic clubfoot.

The youngster is put in a comfortable supine posture and the limb is stabilized to stop compensatory movements using an electronic goniometer. The goniometer is positioned about the joint's anatomical landmarks, such as the ankle's lateral malleolus, fifth metatarsal, and fibular head. Following a passive movement of the joint across its entire range, the apparatus automatically

records the angle and shows it on a digital screen. Studies have demonstrated that when used to assess pediatric Orthopedic conditions, such as clubfoot, electronic goniometers produce great intra- and inter-rater reliability (19, 20).

### Treatment procedures

The equinus component of the deformity is caused by spastic plantar flexor muscles, which were targeted by intramuscular injections of BTX-A into the gastrocnemius-soleus complex in all individuals. To guarantee accuracy and safety, the dosage was measured according to the child's weight and given under ultrasound monitoring (21).

Children in the study group had an intense physiotherapy program to improve their functional alignment, joint mobility, and muscle balance after the injection. Within a week following the BTX-A injection, the program began, and it lasted for eight weeks with five sessions per week. Passive stretching, manual mobilization, strengthening exercises, weight-bearing activities, and task-specific functional training were all incorporated into the about 60-minute sessions. To address residual abnormalities and strengthen motor control, special attention was paid to ankle dorsiflexion stretching, subtalar joint mobilization (22). The intense physiotherapy program was not offered to the control group; instead, they were given the normal care protocol, which included an injection of botulinum toxin followed by regular stretching exercises and orthotic bracing (23) (Figure 1).

### Statistical Analysis

Descriptive statistics of mean and standard deviation presented the children's age, weight and height. The paired and unpaired t-test was used to compare the pre-and post-treatment values of intensive physical therapy following botulinum toxin A injection in the treatment of club foot, within and between the groups. Non-parametric tests (The Wilcoxon signed rank test and the Mann-Whitney test) were used to analyze the pre-and post-treatment values of Pirani and ROM within and between the groups. A p-value of less than 0.05 was taken as significant.

### Results

#### Demographic data

We have checked the equivalence of the traditional physiotherapy (TPT) and intensive physiotherapy (IPT) groups in age, weight, and height before the intervention. Table 1 presents the characteristics of both groups to be matched at the baseline. No significant differences were recorded ( $p > 0.05$ ) (Table 1).

It is indicated from Table 2 that no statistically significant differences were observed between groups at baseline, indicating good comparability (all  $p$ -values  $> 0.05$ ) (Table 2).

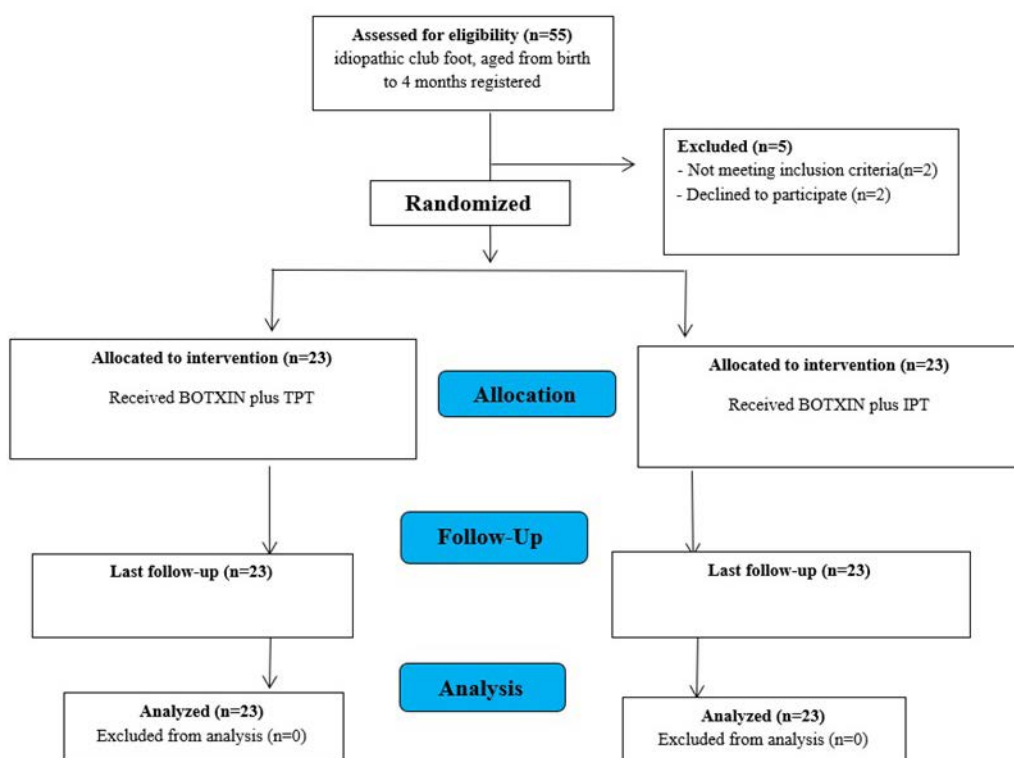


Figure 1. Consort flow chart for patients in the study.

**Table 1.** Demographic characteristics of children in both groups.

Items	TPT group (x ± SD)	IPT group (x ± SD)	t-value	p-value
Age (months)	2.6 ± 1.046	2.85 ± 0.875	0.82	0.418*
Weight (kg)	5.32 ± 1.319	5.485 ± 0.955	0.453	0.653*
Height (cm)	57 ± 10.916	59.25 ± 8.045	0.742	0.463*

X: Mean; t: Student t-test. SD: Standard deviation; \*: Non-significant

**Table 2.** Statistical analysis of Pirani score within each group and between groups of children with idiopathic club foot.

Item	Pre (X±SD)	Post (X±SD)	MD	t-value	p-value
<b>Posterior Heel Crease</b>					
TPT group	0.375±0.425	0.425±0.466	0.05	0.37	0.716
IPT group	0.65±0.366	0.35±4.08	0.3	2.349	0.03**
MD	0.275	0.075			
t-value	2.191	0.527			
p-value	0.035*	0.601			
<b>Empty Heel Sign</b>					
TPT group	0.375 ±0.425	0.4±0.417	0.025	0.181	0.0.858
IPT group	0.725±0.343	0.425±0.438	0.3	2.108	0.049**
MD	0.35	0.025			
t-value	2.864	0.185			
p-value	0.007*	0.854			
<b>Rigid Equinus</b>					
TPT group	0.425±0.438	0.45 ± 0.426	0.025	0.165	0.871
IPT group	0.7±0.251	0.475 ±0.413	0.225	2.131	0.046**
MD	0.275	0.025			
t-value	2.437	0.188			
p-value	0.02*	0.852			
<b>Medial Crease</b>					
TPT group	0.4±0.417	0.425 ± 0.438	0.025	0.165	0.871
IPT group	0.625±0.358	0.475±0.443	0.15	1.189	0.249
MD	0.225	0.05			
t-value	1.831	0.359			
p-value	0.075	0.722			
<b>Curved Lateral Border</b>					
TPT group	0.45 ±0.426	0.45±0.456	0	0	1
IPT group	0.65±0.235	0.4±0.417	0.25	2.364	0.029**
MD	0.2	0.05			
t-value	1.838	0.362			
p-value	0.074	0.719			
<b>Lateral Head of Talus</b>					
TPT group	0.45±0.426	0.425 ± 0.406	0.025	0.213	0.834
IPT group	0.725±0.255	0.475 ±0.413	0.25	2.364	0.029**
MD	0.275	0.05			
t-value	2.476	0.386			
p-value	0.018*	0.702			
<b>Total Pirani Score</b>					
TPT group	2.475±0.786	2.575 ± 1.042	0.1	0.351	0.729
IPT group	4.075±0.977	2.6±1.153	1.475	3.997	0.001**
MD	1.6	0.025			
t-value	5.706	0.072			
p-value	0.000*	0.943			

X: Mean, p: Level of significance, SD: Standard deviation; \*\*: Significant, t; Student t-test; \*\*: Significant.

It is noted from Table 2 that the differences between the pre- and post-measurements of the TPT group are all insignificant. It is also noted that the differences between the pre- and post-measurements of the IPT group are all significant in favour of the post-measurement, with the least Pirani, except for the Medial Crease variable, which was not significant. Comparing the TPT and IPT groups before and after the intervention, before the intervention, all differences were significant in favour of the IPT group with the lowest Pirani score, but after the intervention, the differences between the two groups

**Table 3.** Statistical analysis of Ankle dorsiflexion with the knee flexion and extension within each group and between groups of children with idiopathic club foot.

Item	Pre (X±SD)	Post (X±SD)	MD	t-value	p-value
<b>Ankle dorsiflexion with knee flexion</b>					
TPT	10.5 ±2.33	11± 1.97	0.5	0.901	0.379
IPT	10.3±2.029	19.95±2.625	9.65	11.566	0.000**
MD	0.2	8.95			
t-value	0.29	12.187			
p-value	0.774	0.000**			
<b>Ankle dorsiflexion with knee extension</b>					
TPT	5.15±2.777	6.35± 2.159	1.2	1.82	0.085
IPT	5.7 ±2.386	10±1.214	4.3	6.886	0.000**
MD	0.55	3.65			
t-value	0.672	6.591			
p-value	0.506	0.000**			

X: Mean; p: Level of significance; SD: Standard deviation; \*\*: Significant; t: Student t-test

became insignificant, which means that the intervention helped the group with the highest Pirani score to approach the group with the lowest Pirani score.

**Ankle dorsiflexion**

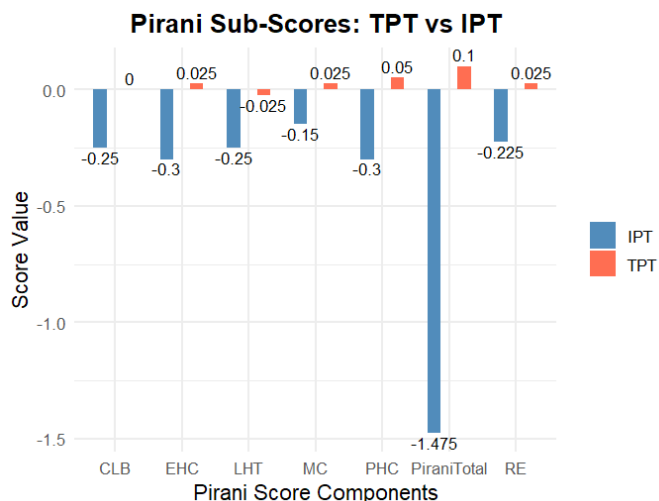
(Table 3) It is noted from Table 3 that the differences between the pre- and post-measurements of the TPT group are all insignificant. It is also noted that the differences between the pre- and post-measurements of the IPT group are all significant in favor of the post-measurement, with the greater Ankle dorsiflexion angle. Comparing the TPT and IPT groups before and after the intervention, before the intervention, all differences were not significant between the TPT and IPT groups, but after the intervention, the differences between the two groups became significant in favor of the IPT group with the greater Ankle dorsiflexion angle in both knee flexion and knee extension, which means that the IPT-based intervention helped this group more than the TPT group (Figure 2, Figure 3).

**Discussion**

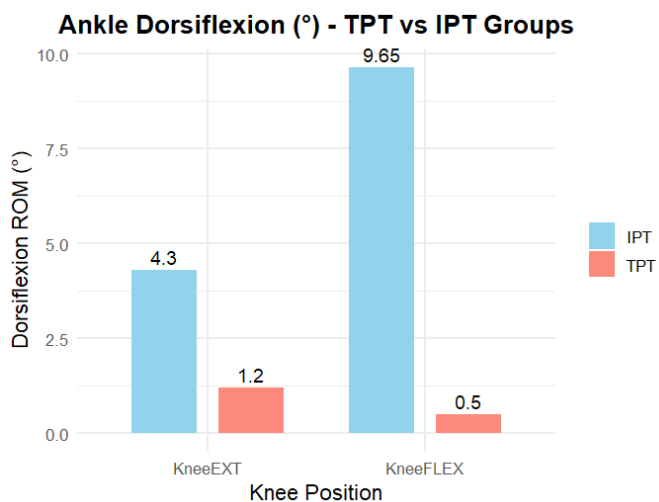
This study evaluates how well a rigorous physiotherapy program works for kids with idiopathic clubfoot who have had a BTX-A injection. The findings demonstrated statistically significant improvements in the Pirani Score, which assesses the severity of club foot. The scale measures six clinical symptoms of deformity, which are divided into three parts for the midfoot (medial crease, curved lateral border, and prominence of the lateral head of the talus) and three parts for the hind foot (stiff equinus, empty heel, and posterior crease). It also measures notable improvements in passive range of motion (PROM) for the ankle joint (dorsiflexion with knee flexion and extension) using an electronic goniometer.

Clubfoot should be treated as soon as possible after birth, preferably in the first three weeks (24). Early treatment yields better outcomes since an infant's bones and joints are more flexible, making it easier and requiring less intrusive treatments to repair the deformity. The bone structures may change as a result of functional injury brought on by inadequate or incorrect therapy (25). So that in our study chose the age of children from birth to four months.

The results of this study demonstrate the benefits of treating children with idiopathic clubfoot by combining an intense physiotherapy program with injections of botulinum toxin type A (BTX-A). this come in agreement with Sharma et al. (26) who demonstrate that Two promising therapy approaches for children with cerebral palsy (CP) include physical exercises and injections of botulinum toxin, which improve functions and make it easier for them to use their damaged limb. BoNT-A can be injected into spastic limb muscles to reduce tone and enhance function. Combining these two interventions would therefore boost functional gains in the limbs that are compromised in children with cerebral palsy.



**Figure 2.** Comparison between IPT and TPT groups in (PHC, EHC , RE, MC, CLB, LHT, Pirani total).



**Figure 3.** relates to the ankle dorsiflexion variable.

According to Alvarez et al. (27) who say that the results of BTX-A treatment for idiopathic clubfoot remained positive at the 2- to 5-year mark. Support for the efficacy of BTX-A in the initial correction and ongoing management of idiopathic clubfoot is provided by the experience with this group.

When comparing the TPT and IPT groups before and after the intervention, all of the differences were significant in favor of the IPT group with the lowest Pirani score. However, after the intervention, the differences between the two groups were no longer significant, indicating that the intervention had a positive effect on the group with the highest Pirani score's ability to approach the group with the lowest Pirani score.

This comes with agreement with a paper which demonstrates that after receiving a BTX-A injection, intensive physical treatment is essential for preserving the biomechanical adjustments made and encouraging neuromuscular adaptation. The study's physiotherapy program included balance training, gait retraining, active strengthening of the dorsiflexors and evertors, and passive stretching. Together, these components strengthen general function, prevent deformity from recurring, and increase motor control. Tarakcii et al. (2022) found similar results, observing notable enhancements in functional outcomes in children who received structured physical therapy after BTX-A) (28).

BekN et al. (2000) explain that while the Ponseti method is still being studied, a substantial improvement can be achieved by incorporating intense physiotherapy procedures into the treatment of pes equinovarus (PEV) (29). When compared to patients who receive a home program, an extensive physical therapy program lessens the degree of deformity, gives the patient a more functional foot, and keeps the patient and family better informed about the issue (30).

Incorporating rigorous physical therapy after BTX-A injections could provide a holistic approach to treating idiopathic clubfoot, thereby lowering the need for surgery and enhancing functional results. To create standardized procedures and evaluate long-term efficacy, more research is necessary. In conclusion, intense physiotherapy seems to improve treatment outcomes even though BTX-A injections offer a non-surgical substitute in the Ponseti approach. The significance of comprehensive care in idiopathic clubfoot is highlighted by the potential synergistic advantages of a coordinated strategy (31).

Souchet et al.'s study covered 779 feet and all patients treated with physical therapy methods for clubfoot between 1993 and 2010. The International Clubfoot Study Group (ICFSG) rating system shows that 86% of these individuals had excellent to good results with just minor radiological flaws or residual deformities. Daily physiotherapy sessions are the foundation of this conservative clubfoot treatment strategy, which aims to achieve a gradual and painless correction. It adheres to predetermined steps, guaranteeing a steady increase in foot alignment (32).

Examine the length passive force curve of muscle contraction in order to have a better understanding of triceps surae muscle complex weakness. Cutting the Achilles tendon should theoretically change the connection between the actin and myosin filament overlap (33). As the muscle contracts, this permits the filaments to overlap more. As a result, the muscle may attain less extension, which lowers power output. The relaxation caused by BTX-A probably results in the muscle lengthening and a decrease in myofibril overlap (34). However, only the units exposed to the BTX-A relaxant were affected; hence, the effect on the muscle fiber overlap was lessened (35).

The BTO pathway may potentially be a more physiologically sound way to increase the range of motion in the back of the foot while maintaining muscle fiber extension and, eventually, power production. This method also enables repeated injections without causing irreversible harm to the physiology of the triceps surae muscles, resulting in preserved functional outcomes (36).

Physical rehabilitation has a positive impact on a child's body, leading to improvements in physical development, functional indicators, and physical attributes to match peers without developmental violations, normalization of foot morphology and function, elimination of relapses, and training of primary movements. Physiotherapy (common procedures, daily, no more than three times 10-30 minutes during the major and final stages of the program implementation), orthopaedic means, footwear, and specific physical activities during exercise treatment are the main means of influence (37).

Comparing the TPT and IPT groups before and after the intervention, before the intervention, all differences were not significant between the TPT and IPT groups, but after the intervention, the differences between the two groups became significant in favours of the IPT group with the greater Ankle dorsiflexion angle in both knee flexion and knee extension. Mindler et al, our findings showed a considerable increase in ankle dorsi and plantar flexion range of motion following therapy. As a result, our physiotherapy program might help with gait behaviour (38,39).

**Conclusion**

Our results indicate that early rehabilitation outcomes for children with idiopathic clubfoot are improved by implementing an intense physiotherapy program after botulinum toxin type A (BTX-A) injection. The addition of structured, post-injection physiotherapy, which included stretching, strengthening, and gait training, was linked to more significant improvements in joint mobility and functional performance, which mirrored improvements observed in comparable pediatric spasticity interventions, even though BTX-A alone only produced modest gains in ankle dorsiflexion and tone reduction. These findings provide credence to a multimodal strategy in which BTX-A serves as a facilitator, but physiotherapy continues to be the primary source of significant clinical improvements.

Future randomized trials should evaluate the results of intense physiotherapy and standard casting plus BTX-A to casting plus BTX-A alone to confirm the combined regimen's long-term effectiveness in lowering relapse rates, enhancing gait, and maybe lowering the need for surgery.

**References**

1. Wang H, Barisic I, Loane M, Addor MC, Bailey LM, Gatt M, Klungsoyr K, Mokoroa O, et al., Congenital clubfoot in Europe: A population-based study. *Am J Med Genet A* 2019; 179: 595-601 [PMID: 30740879 DOI: 10.1002/ajmg.a.61067]
2. Gurnett CA, Boehm S, Connolly A, Reimschisel T, Dobbs MB. Impact of congenital talipes equinovarus etiology on treatment outcomes. *Dev Med Child Neurol* 2008; 50: 498-502 [PMID: 18611198 DOI: 10.1111/j.1469-8749.2008.03016.x]
3. Ostadal M, Liskova J, Hadraba D, Eckhardt A. Possible pathogenetic

- mechanisms and new therapeutic approaches of pes equinovarus. *Physiol Res.* 2017;66(3):403-10. [PubMed ID: 28248538]. <https://doi.org/10.33549/physiолres.933404>.
4. Hegazy MA, Khairy HM, Hegazy AA, El-Aidy SM. Clubfoot in children: An overview. *Foot Ankle Online J.* 2020;13(10):1-12.
  5. Anand A, Sala DA. Clubfoot: etiology and treatment. *Indian J Orthop.* 2008;42(1):22-8. [PubMed ID: 19823650]. [PubMed Central ID: PMC2759597]. <https://doi.org/10.4103/0019-5413.38576>.
  6. Cady R, Hennessey TA, Schwend RM. Diagnosis and Treatment of Idiopathic Congenital Clubfoot. *Pediatrics.* 2022;149(2). [PubMed ID: 35104362]. [PubMed Central <https://doi.org/10.1542/peds.2021-055555>]. 7. ID: PMC9645716].
  7. Wilner, A., & Schwend, R. M. (2022). Diagnosis and Treatment of Idiopathic Congenital Clubfoot.
  8. Ayoub N. Botulinum toxin therapy: a comprehensive review on clinical and pharmacological insights. *J Clin Med.* 2025;14(6):2021. doi: 10.3390/jcm14062021.
  9. Francisco GE, Wissel J, Platz T, et al. Clinical pathways in stroke rehabilitation: evidence-based clinical practice recommendations. *Cham (CH): Springer;* 2021. Jan 15. In: 36315691. *Post-Stroke Spasticity.*, editor. [Internet].
  10. Zhu C, Li L, Qiu L, et al. Risk factors for post-stroke spasticity: a retrospective study. *Front Neurol.* 2024;15: 1478206. doi: 10.3389/fneur.2024.1478206.
  11. Liu YF, Li YJ, et al. Interactive scalp acupuncture for upper limb dysfunction after ischemic stroke: a randomized controlled trial. *Chinese Acupunct Moxibust.* 2023;43(10):1109-1113. In Chinese).
  12. Alvarez, C. M., Tredwell, S. J., Keenan, S. P., Beauchamp, R. D., Choit, R. L., Sawatzky, B. J., & De Vera, M. A. (2005). Treatment of idiopathic clubfoot utilizing botulinum A toxin: a new method and its short-term outcomes. *Journal of Pediatric Orthopaedics*, 25(2), 229-235].
  13. Tarakci, D., Leblebici, G., Tarakci, E., & Bursali, A. (2022). The effectiveness of three-phase physiotherapy program in children with clubfoot after Ponseti treatment. *Foot and Ankle Surgery*, 28(2), 181-185.
  14. Mejabi JO, Esan O, Adegbehingbe OO, Orimolade EA, Asuquo J, Badmus HD, Anipole AO. The Pirani Scoring System is Effective in Assessing Severity and Monitoring Treatment of Clubfeet in Children , *British Journal of Medicine & Medical Research* 17(4): 1-9, 2016
  15. Dyer PJ, Davis N. The role of the Pirani scoring system in the management of club foot by the Ponseti method. *Bone & Joint Journal.* 2006 Aug 1;88(8):1082-4.
  16. Irani S, Hodges D & Sekeramayi F (2003) A reliable and valid method of assessing the amount of deformity in the congenital clubfoot deformity (The Canadian Orthopaedic Research Society and the Canadian Orthopaedic Association conference proceeding) in *The Journal of Bone and Joint Surgery* 90 (B) SUPP\_1, 53
  17. Jillani SA, Aslam MZ, Chinoy MA, Khan MA, Saleem A, Ahmed SK. A comparison between orthopedic surgeon and allied health worker in Pirani score. *J Pak Med Assoc.* 2014 Dec;64(12 Suppl 2):S127-30.
  18. Papadopoulos ES, Papageorgiou E, Papadopoulou S, Kirkos JM. Objective assessment of ankle joint mobility in clubfoot using electronic goniometry. *J Pediatr Orthop B.* 2015;24(5):437-443.
  19. Carvalho GA, de Souza RC. Range of motion evaluation in clubfoot: comparison between digital and universal goniometers. *Foot Ankle Surg.* 2018;24(1):67-71.
  20. Smith TO, Davies L, Hing CB, Toms AP, Donell ST. A systematic review to determine the reliability of measuring passive ankle dorsiflexion in children. *Physiotherapy.* 2012;98(4):279-286
  21. Dobbs MB, Gurnett CA. Update on clubfoot: etiology and treatment. *Clin Orthop Relat Res.* 2009 May;467(5):1146-1153. doi:10.1007/s11999-009-0724-9.
  22. Radler C, Mindler GT. Treatment of clubfoot: current status and future perspectives. *Arch Dis Child.* 2013 Sep;98(9):793-797. doi:10.1136/archdischild-2012-302852.
  23. Kuijk AA, van der Heide HJ, Veenhuizen Y, Backx FJG. Botulinum toxin A in the management of idiopathic toe-walking and clubfoot: clinical review. *Medscape (eMedicine).* 2022; Article on chemodeneration and orthotic management.
  24. Böhm S, Sinclair M. Report of the 1st European consensus meeting on Ponseti clubfoot treatment. *J Child's Orthopaedics.* 2013;7(3):251-4. <https://doi.org/10.1007/s11832-013-0497-4>.
  25. Islam MS, Masood QM, Bashir A, Shah FY, Halwai MA. Results of a Standard versus an Accelerated Ponseti Protocol for Clubfoot: A Prospective Randomized Study. *Clin Orthop Surg.* 2020;12(1):100-6. [PubMed ID: 32117545]. [PubMed Central ID: PMC7031442]. <https://doi.org/10.4055/cios.2020.12.1.100>.
  26. Sharma, A., Vats, S., & Chahal, A. (2022). Physical exercises in combination with botulinum toxin in treating children with cerebral palsy: A literature review. *Journal of Lifestyle Medicine*, 12(3), 138.
  27. Alvarez, C. M., De Vera, M. A., Chhina, H., Williams, L., Durlacher, K., & Kaga, S. (2009). The use of botulinum type A toxin in the treatment of idiopathic clubfoot: 5-year follow-up. *Journal of Pediatric Orthopaedics*, 29(6), 570-575.
  28. Tarakci, D., Leblebici, G., Tarakci, E., & Bursali, A. (2022). The effectiveness of three-phase physiotherapy program in children with clubfoot after Ponseti treatment. *Foot and Ankle Surgery*, 28(2), 181-185.
  29. BekN, Uygur F, Yakut Y, Kürklüb. An inquiry into the efficiency of active physical therapy program in patient with congenital pes equinovarus]-*Tur. Fizyoter. Rehabil.* 2000; 11: 75-82.
  30. Bensahel H, Jehanno P, Delaby JP, Themar-Noël C. Conservative treatment of clubfoot: The Functional Method and its long-term follow-up. *Acta Orthop. Traumatol. Turc.* 2006; 40: 181-6.
  31. Alvarez, C. M., Wright, J. G., Chhina, H., Howren, A., & Law, P. (2018). Botulinum toxin type A versus placebo for idiopathic clubfoot: a two-center, double-blind, randomized controlled trial. *JBJS*, 100(18), 1589-1596.
  32. Souchet P, Delaby JP, Campana M, Chinnappa J, Ilharrebordé B, Simon AL. The functional method: experience from the Robert Debre Hospital. *Ann Transl Med.* 2021;9(13):1098. [PubMed ID: 34423010]. [PubMed Central ID: PMC8339822]. <https://doi.org/10.21037/atm-20-7727>.
  33. Pirani S. Ponseti treatment of the congenital clubfoot: The New Westminster experience. *International Society of Orthopaedic Surgery and Traumatology 3rd International Clubfoot Congress, San Diego, California, August 2002.*
  34. Herzenberg JE, Radler CR, Bor N. Ponseti versus traditional methods of casting for idiopathic clubfeet. *J Pediatr Orthop.* 2002; 22:517-521.
  35. Mooney JF, Koman LA, Smith BP. Pharmacologic management of spasticity in cerebral palsy. *J Pediatr Orthop.* 2003; 23:679-686.
  36. Morcuende JA, Dolan LA, Ponseti IV. Efficacy of the Ponseti method in the treatment of idiopathic clubfoot. *International Society of Orthopaedic Surgery and Traumatology 3rd International Clubfoot Congress, San Diego, California, August 2002.*
  37. Nesterchuk, N., Grygus, I., Prusik, K., & Zukow, W. (2019). The technique of physical rehabilitation in clubfoot. *Physiotherapy Quarterly*, 27(1), 25-34.
  38. Mindler GT, Kranzl A, Lipkowski CAM, Ganger R, Radler C. Results of gait analysis including the oxford foot model in children with clubfoot treated with the ponseti method. *J Bone Joint Surg Am* 2014;96(19):1593-9, doi: <http://dx.doi.org/10.2106/JBJS.M.01603.1>
  39. El-Sayed, M. S., Kilany, A., & El Shemy, S. A. (2025). Efficacy of Task-Oriented Circuit Training on Gait Kinematics, Pelvic Symmetry and Trunk Endurance in Children with Hemiplegia: A Randomized Controlled Trial. *Journal of musculoskeletal & neuronal interactions*, 25(1), 36-46. <https://doi.org/10.22540/JMNI-25-036>